

Ridge Preservation using Porcine Xenograft and dPTFE Membrane

Gustavo Avila-Ortiz, DDS, MS, PhD

Associate Professor and Graduate Program Director, Department of Periodontics, University of Iowa College of Dentistry

Chris Barwacz, DDS, FAGD

Assistant Professor, Department of Family Dentistry, University of Iowa College of Dentistry

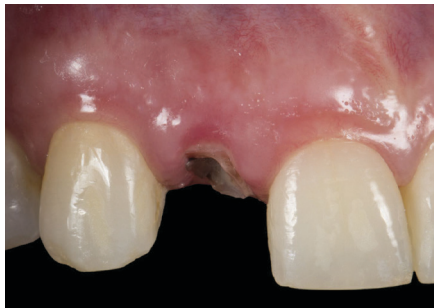

Fig 1a

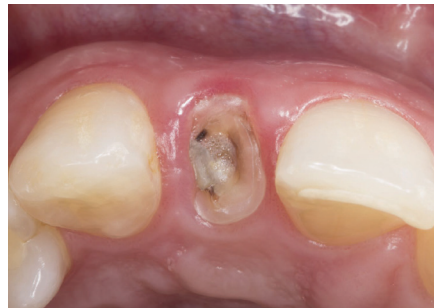

Fig 1b

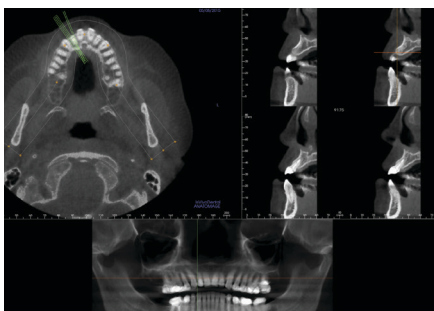


Fig 2a

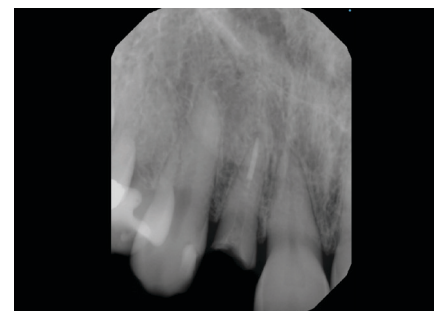


Fig 2b

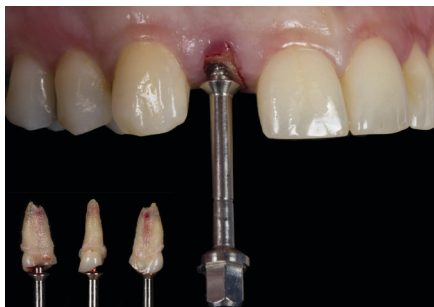

Fig 3

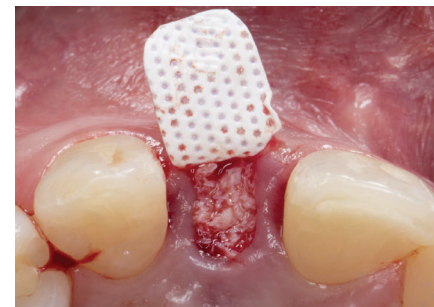


Fig 4

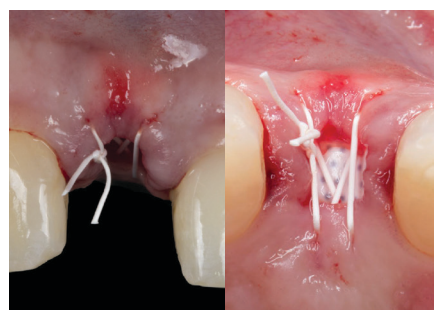


Fig 5

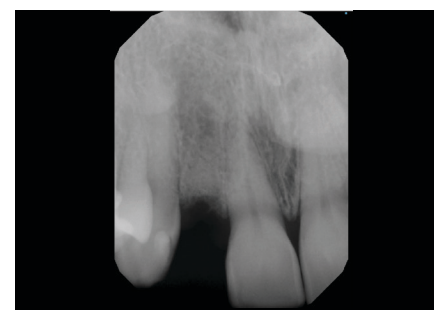


Fig 6

A 47-year old female with no contributory medical history presented with a cervical tooth fracture on the right maxillary lateral incisor (Fig 1a & 1b). A thorough clinical examination was conducted. All periodontal parameters were normal, except for BOP on the mid-facial. Plaque control was adequate. A CBCT scan and a periapical radiograph indicated normal interproximal bone levels, and the thickness of the buccal bone ranged from 0.6 to 0.9 mm (Fig 2a & 2b). Different treatment options were considered, including tooth conservation and tooth-supported FPD, but patient opted for tooth replacement with an implant-supported prosthesis.

The remaining tooth structure was extracted in a minimally invasive fashion to avoid damage to the supporting hard and soft tissue structures (Fig 3). Following meticulous debridement and irrigation of the socket, subperiosteal pockets were created on the buccal and lingual aspects of the alveolar ridge. A dPTFE (dense polytetrafluoroethylene) membrane (Cytoplast™ TXT Singles) was gently tucked into the buccal pocket and porcine-derived cancellous xenograft particles (Zcore™) were placed in the socket, up to the level of the crestal bone (Fig 4). The dPTFE membrane was then tucked into the lingual pocket and a horizontal cross mattress suturing technique using PTFE suture (Cytoplast™ PTFE Suture 4-0) was placed to secure the membrane and stabilize the soft tissue margins (Fig 5). The application of a dPTFE membrane allows for a conservative regenerative approach that does not require primary closure via buccal flap advancement. Immediately following this ridge preservation procedure, a periapical radiograph was taken to verify that the xenograft particles were level with the crestal bone (Fig 6). Before dismissal, patient was instructed to clean the exposed membrane area by carefully swabbing twice daily with a cotton pellet soaked in Chlorhexidine 0.12% aqueous solution.

Suture removal occurred at the one week post-op appointment and soft tissue healing was progressing as predicted. The dPTFE membrane was visible through the soft tissue

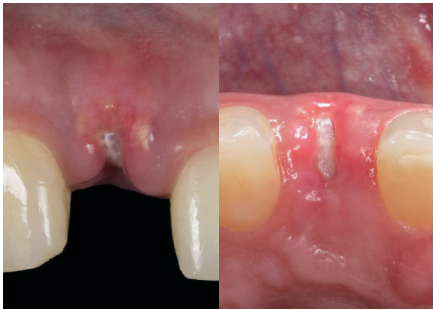

Fig 7

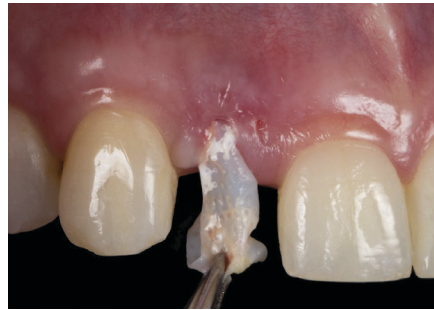

Fig 8a

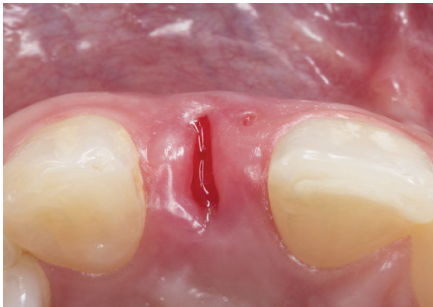


Fig 8b

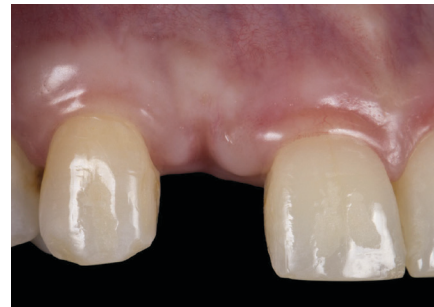

Fig 9

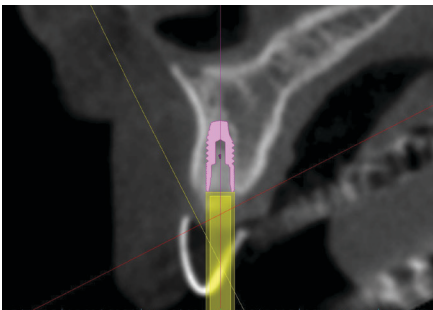


Fig 10

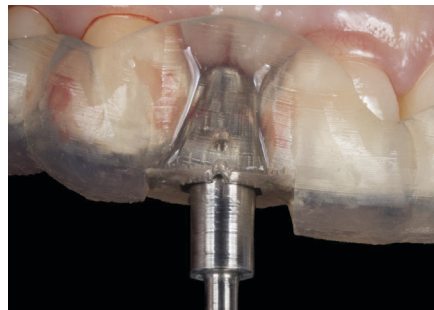

Fig 11

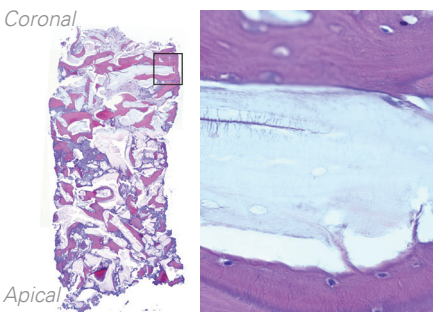


Fig 12a

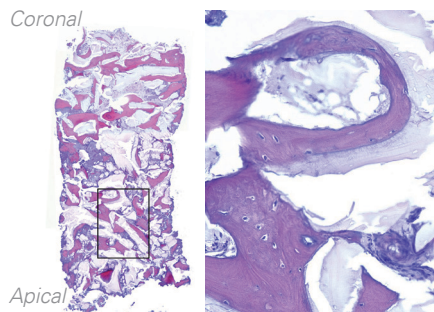


Fig 12b

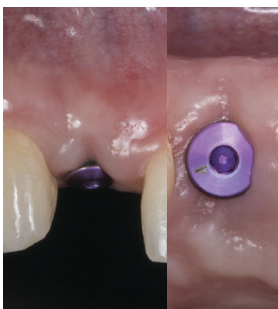


Fig 13

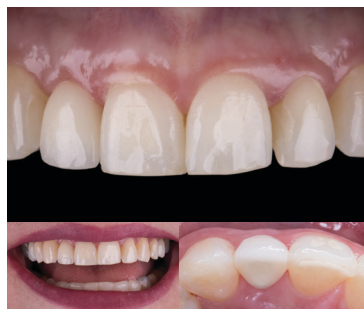

Fig 14

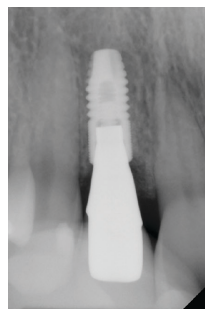


Fig 15

and the membrane had remained in the original site of placement.

At 3 weeks, non-disturbed healing continued. Keratinized tissue was preserved and no signs of inflammation or swelling were present (Fig 7).

At 6 weeks, the membrane was removed using tissue forceps (Fig 8a). Upon clinical examination, the soft tissue architecture had remained intact. Slight bleeding could be observed around the perimeter of the wound and in the area immediately underlying the membrane, which is normal (Fig 8b).

At 12 weeks, the soft tissue appears mature and a supracrestal increase in the band of keratinized tissue was visible. Esthetics of the anterior ridge have been preserved at an optimal level (Fig 9).

At 20 weeks, another CBCT scan was obtained. Radiographic evaluation of the site revealed that ridge volume and bone density were adequate to proceed with the plan to surgically place an implant following a computer guided surgery protocol (Fig 10). The implant was placed using a sterilolithic surgical guide at 7 months after tooth extraction. Using a 2.75 mm trephine and the surgical guide, a core of the grafted site was taken for histologic and histomorphometric analysis (Fig 11). The amount of newly formed vital bone was approximately 35%. Excellent integration of the remaining xenograft particles was observed throughout the sample in absence of any inflammatory infiltrate, which illustrates the biocompatibility and the osteoconductive properties of this grafting material (Fig 12a & 12b).

At 1 week following implant placement, an abundance of keratinized tissue is seen, with a portion encroaching the healing abutment (Fig 13).

The final single-tooth implant crown was delivered at 10 weeks after implant placement using a custom zirconia abutment that was hand-layered with porcelain. A natural emergence profile and a very satisfactory esthetic and functional outcome was achieved (Fig 14). A periapical radiograph was taken to verify the maintenance of normal marginal bone levels and absence of pathosis (Fig 15).